

# Cluster headache: pathogenesis, diagnosis, and management

Arne May

Cluster headache is a stereotyped primary pain syndrome characterised by strictly unilateral severe pain, localised in or around the eye and accompanied by ipsilateral autonomic features. The syndrome is characterised by the circadian rhythmicity of the short-lived attacks, and the regular recurrence of headache bouts, which are interspersed by periods of complete remission in most individuals. Headaches often start about 1–2 h after falling asleep or in the early morning, and show seasonal variation, suggesting that the hypothalamus has a role in the illness. Consequently, the vascular theory has been superseded by recognition that neurovascular factors are more important. The increased familial risk suggests that cluster headache has a genetic component in some families. Neuroimaging has broadened our pathophysiological view and has led to successful treatment by deep brain stimulation of the hypothalamus. Although most patients can be treated effectively, some do not respond to therapy. Fortunately, time to diagnosis of cluster headache has improved. This is probably the result of a better understanding of the pathophysiology in combination with efficient treatment strategies, leading to a broader acceptance of the syndrome by doctors.

Lancet 2005; 366: 843–55

Department of Systems Neuroscience, Universitäts-Krankenhaus Eppendorf, Martinistr 52, D-20246 Hamburg, Germany (A May MD) a.may@uke.uni-hamburg.de

## Clinical features

“Imagine, your eye is pushed out of its socket and your right eyelid is beginning to swell shut. You start squinting and your eye is tearing, you are convinced there was blood pouring out. A red-hot knife is crushed into your head, excruciating, horrible, horrible pain. Your only saving grace is to pace from room to room, crying, flinging yourself to the floor, until eventually the pain drains from you. Waiting for the next attack to happen is a terrible, scary feeling. I sometimes think that I will go mad. I’m exhausted but then the next one hits.”

This is an example of how a cluster headache patient might describe his pain in an outpatient setting. Cluster headache, one of the most severe pain syndromes—female patients describe each attack as being worse than childbirth—is still underdiagnosed and suboptimally managed in primary care.<sup>1</sup> Results of a recent health-related quality-of-life study in 56 patients suggest that cluster headache has substantial effects on patients’ ability to function, even when appropriate treatments are used.<sup>2</sup> Typically, attacks can strike up to eight times a day, are relatively short-lived, and are characterised by strictly unilateral severe head pain accompanied by autonomic symptoms.<sup>3</sup> A side shift is mentioned in only about 15% of cases.<sup>4</sup> Unlike individuals with migraine, patients with cluster headache are restless and prefer to pace about or sit and rock back and forth. Some patients will exert pressure on the painful area with a hand over the affected eye and temple. Many will isolate themselves during the headache or leave the house to get into cold or fresh air, and tend to become aggressive during an attack.

The unilateral autonomic symptoms such as ptosis, miosis, lacrimation, conjunctival injection, rhinorrhoea, and nasal congestion occur only during the pain attack and are ipsilateral to the pain, indicating parasympathetic hyperactivity and sympathetic impairment (figure 1). In some patients, the signs of sympathetic paralysis (miosis and ptosis) persist indefinitely,<sup>5</sup> but intensify during attacks. Sweating and

bloodflow to the skin also increase on the painful side, particularly in areas of sympathetic deficit.<sup>6</sup> About 3% of patients have no autonomic symptoms,<sup>7</sup> and in rare cases sympathetic disturbances persist on the previously affected side of the face in patients in whom cluster headaches have switched sides.<sup>8</sup>

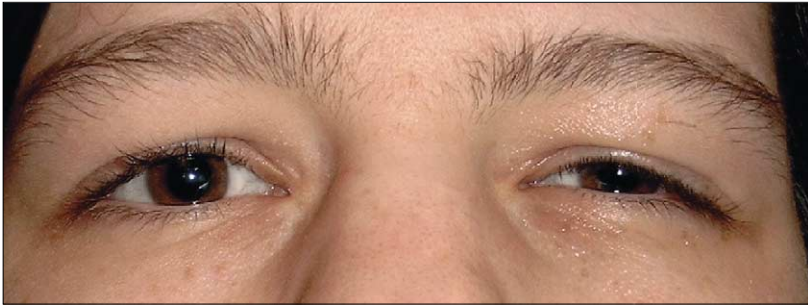Another clinical feature of the syndrome is the circadian rhythmicity of the painful attacks, which are relatively short (15–180 min). In the episodic form, headaches occur daily for some weeks followed by a period of remission. On average, a cluster period lasts 6–12 weeks, and remissions can last up to 12 months. In the chronic form, attacks occur without substantial periods of remission. When chronic cluster headache is unresponsive to medical treatments, it becomes a serious problem and surgical options may have to be considered.

## Epidemiology and genetics

Compared with migraine, cluster headache is uncommon.<sup>9–11</sup> The disorder has a prevalence of less than 1%,<sup>12</sup> and mostly affects men.<sup>13,14</sup> The episodic form is most common, affecting 80–90% of cluster headache patients. It is characterised by periods of headaches (clusters or bouts) and periods of remission. During a

### Search strategy and selection criteria

I searched MEDLINE with the keywords “cluster headache”, “trigemino-autonomic headache”, “paroxysmal hemicrania”, “SUNCT”, “pathophysiology”, “treatment”, and “trial” (last search in January, 2005). All papers published in English or German were considered when they described a controlled trial or a case series on the treatment of at least five patients (or fewer in paroxysmal hemicrania or SUNCT syndrome). Papers located by this search were reviewed, as were references cited therein. Additionally, review books and the German treatment recommendations for cluster headache<sup>84</sup> were considered.



**Figure 1: Patient soon after a left-sided cluster headache attack**  
Note the Horner syndrome ipsilateral to the headache and increased facial sweating exclusively around the left eye.

bout, patients may experience one to eight attacks per day, and bouts can last from 7 days to 12 months.<sup>3</sup> While in remission, patients are usually asymptomatic. The chronic form of cluster headache lacks remissions, and is diagnosed after a year without remission or if remission has lasted less than 30 days. A chronic cluster may arise *de novo* (primary chronic cluster headache) or evolve from the episodic type (secondary chronic cluster headache).

One of the most urgent questions patients put to their doctors is whether, as in migraine, the cluster attacks decline with age. Longitudinal data for cluster headache are anecdotal and only recently have data from larger epidemiological studies become available;<sup>13,15</sup> overall, the authors of these reports assume that within the natural course of the condition, the symptoms remit with age.

The largest epidemiological study to date reports data for about 550 patients with episodic and chronic cluster headache over an observation period of more than 30 years (1963–97).<sup>16</sup> In this study, there was a trend towards a decreasing male preponderance; the male-to-female ratio was substantially higher among patients with onset before 1970 than in those with onset after 1970, whereas the proportion of episodic to chronic form did not change during the study period. According to prospective studies, the syndrome occurs about three times more often in men than in women, and is clinically identical in both sexes.<sup>13</sup> Mechanisms associated with sex hormone regulation, and environmental factors related to lifestyle, have been suggested to account for the increase in numbers of women diagnosed with cluster headache since 1970.<sup>16</sup> The nature of the sex-related and age-related pattern of cluster headache onset is unclear. However, the increase in the diagnosis in women might also be the result of increased awareness and acceptance of the disorder by doctors, due to improved understanding of cluster headache pathophysiology.<sup>17–22</sup>

The medical history often reveals a high incidence of head trauma with brain concussion,<sup>23–25</sup> but it is hard to prove a cause-and-effect relation. Interestingly, up to 85% of patients with chronic headache are also chronic

cigarette smokers.<sup>23</sup> Quitting smoking has no effect on the disease. The question arises whether chronic nicotine consumption is needed as a trigger to initiate the syndrome, possibly on the basis of some genetic background.

Before 1990, cluster headache was not generally thought to be an inherited disorder.<sup>26,27</sup> However, reports of cluster headache in monozygotic twins<sup>28</sup> and familial occurrence of cluster headache in 7% of families, resulting in a 14-fold increase in risk of cluster headache in first-degree relatives and a two-fold increased risk for second-degree relatives,<sup>29</sup> show that genetic factors should be considered. In a study of 186 index patients and 624 first-degree relatives, investigators showed a positive family history of cluster headache in 11% of the index patients. They concluded that no precise mode of inheritance could be ascertained.<sup>30</sup> A complex segregation analysis of cluster headache has suggested that an autosomal dominant gene has a role in some families,<sup>31</sup> although some evidence exists for autosomal recessive or multifactorial inheritance in others.<sup>12</sup> However, future studies should take into account that since cluster headache can start between the ages of 7 years<sup>32</sup> and 83 years,<sup>33</sup> the distinction between affected and unaffected individuals is clearly provisional. To date, the increased familial risk strongly supports the hypothesis that cluster headache has a genetic component, at least in some families.<sup>21</sup> However, no clear molecular genetic clues have yet been identified. In view of the paroxysmal character and circadian and circannual rhythmicity of the disease, future studies need to focus on ion channel genes and clock genes.

### Pathophysiology

Although the syndrome is well defined from a clinical point of view<sup>3</sup> and has been recognised for more than two centuries,<sup>34</sup> its pathophysiology is still poorly understood. However, the past decade has seen remarkable progress toward solving the pathophysiological puzzle.<sup>22</sup> Any pathophysiological model needs to explain the three major features of cluster headache: trigeminal distribution of the pain, ipsilateral cranial autonomic features, and (circadian) episodic pattern of attacks. The vascular theory, which is based on an inflammation of the walls of the cavernous sinus (the only peripheral anatomical location where a single pathology could involve trigeminal C-fibres and sympathetic fibres),<sup>35</sup> has been superseded by recognition that neurovascular events and some central impulse generator or oscillator seem to be more important. The severe unilateral pain is likely to be mediated by activation of the first (ophthalmic) division of the trigeminal nerve, whereas the autonomic symptoms such as lacrimation are due to activation of the cranial parasympathetic outflow from the seventh cranial nerve.<sup>36</sup>

### Autonomic features

The sympathetic paralysis (miosis and ptosis) is due to a neuropraxic injury of postganglionic fibres in most patients.<sup>37</sup> Currently, at least three possible sources of the autonomic symptoms are discussed: (1) the autonomic dysregulation might originate centrally in association with a hypothalamic disturbance;<sup>19,38</sup> (2) a vasodilation or perivascular oedema (due to trigeminal-parasympathetic overactivity during attacks) compromises the carotid canal and consequently the traversing sympathetic fibres;<sup>39</sup> and (3) the autonomic symptoms are secondary to trigeminal discharge.<sup>40,41</sup>

The possibility that parasympathetic hyperactivity is solely responsible for ocular sympathetic deficit has been discussed.<sup>42</sup> About 3% of patients have no autonomic symptoms,<sup>7</sup> and patients with and without autonomic symptoms have been described in the same families.<sup>43,44</sup> In rare cases pain and autonomic symptoms may fully dissociate.<sup>45</sup> However, a typical cluster attack will be strictly one-sided and will have prominent ipsilateral autonomic symptoms.<sup>3</sup>

The relapsing-remitting course,<sup>46</sup> its seasonal variation,<sup>46</sup> and the clockwise regularity<sup>47</sup> of single episodes are characteristic, and suggest that the biological clock—namely the hypothalamus—is involved in the origin of the illness.<sup>48–50</sup> Substantially lowered concentrations of testosterone in the plasma of men with cluster headache provided the first evidence of such a role.<sup>51</sup> This evidence is further supported by a reduced response to thyrotropin-releasing hormone<sup>52</sup> and a range of other circadian irregularities that have been reported in patients with cluster headache.<sup>50,53,54</sup> Melatonin, in particular, is a marker of the circadian system; a blunted nocturnal peak in melatonin and complete loss of circadian rhythm have been reported in cluster headache.<sup>53,55</sup> The endogenous circadian rhythm is controlled by an oscillator in the suprachiasmatic nuclei in the ventral hypothalamus, and is entrained to temporal environmental cues by light conditions via a retino-hypothalamic pathway.<sup>56</sup> Clinical observations thus suggest the hypothalamus or a closely related structure as a candidate trigger for the acute attacks of cluster headache.

### Functional imaging

Functional imaging work with PET has confirmed a highly specific activation of the hypothalamic grey matter in nitroglycerin-triggered and spontaneous cluster headaches,<sup>57,58</sup> suggesting involvement in the pain process in a permissive or triggering manner rather than simply a response to first division nociception per se.<sup>17</sup> Although the headache syndromes that form the group known as trigemino-autonomic cephalgias (cluster headache, paroxysmal hemicrania, and short-lasting neuralgiform headache with conjunctival injection and tearing [SUNCT]) share typical clinical features,<sup>59</sup> in most cases a subclassification is possible

and reasonable, as therapeutic regimens and responses differ. Since many of the basic features of SUNCT are shared by cluster headache and paroxysmal hemicrania, investigators have questioned whether there is a shared pathophysiological basis that might be expressed in similar cerebral activation patterns.

### Neuroimaging in related syndromes

Using blood-oxygen-dependent functional MRI, three independent case reports investigating four patients with spontaneous SUNCT episodes uniformly found an activation next to the hypothalamic spot that was activated in cluster headache.<sup>60–62</sup> The same prominent activation in the hypothalamic grey matter was found in a patient suffering from excruciating trigemino-autonomic headaches, in whom frequency and duration of attacks and therapeutic response allowed no clear-cut classification.<sup>63</sup> These findings suggest that the underlying cause of trigemino-autonomic cephalgias might indeed be similar, and the variation in duration and frequency might be generally dependent on a different disorder of the hypothalamic neurons, perhaps a modulation of neuronal activity or a different involvement of the trigeminovascular system. These case studies underline the conceptual value of the term trigemino-autonomic cephalgias for the group of headaches focused around the trigeminal-autonomic reflex. Moreover, these findings emphasise the importance of the hypothalamus as a key region in the pathophysiological process of such headaches.

Another unilateral headache that is accompanied by trigeminal autonomic features is hemicrania continua. It is a strictly unilateral, continuous headache of moderate intensity, with superimposed exacerbations of severe intensity that are then accompanied by autonomic features and migrainous symptoms.<sup>64</sup> The syndrome is exquisitely responsive to indometacin. Although, for theoretical reasons, it is not included among the trigeminal-autonomic headaches,<sup>3</sup> a substantial activation of the contralateral posterior hypothalamus and ipsilateral dorsal rostral pons has been described in seven patients with hemicrania continua.<sup>65</sup> Additionally, there was activation of the ipsilateral ventrolateral midbrain, which extended over the red nucleus and the substantia nigra, and bilateral pontomedullary junction. This study showed that the neuroimaging markers of both the trigeminal autonomic cephalgias (hypothalamus)<sup>22</sup> and migraine (brainstem)<sup>66,67</sup> are noted in hemicrania continua, mirroring the clinical phenotype that, in fact, shows some overlap with trigeminal autonomic headaches and migraine.<sup>65</sup> Taken together, just as in the case of an atypical trigemino-autonomic headache,<sup>63</sup> the functional imaging data in hemicrania continua<sup>65</sup> emphasise that primary headache syndromes can be distinguished on a functional neuroanatomical basis by areas of activation specific to the clinical presentation. However, in view of

the consistency of the PET findings with the clinical presentation, the question remains whether the brain of such patients is indeed structurally normal.

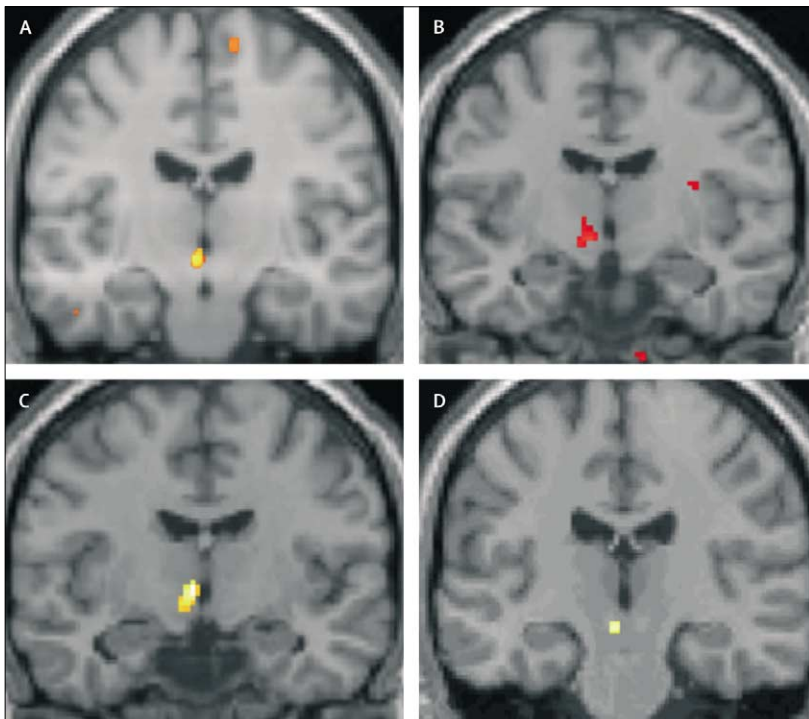
### Hypothalamic deep brain stimulation

Recently, voxel-based morphometry has shown a structural difference in grey matter density—a lesion coinciding with the inferior posterior hypothalamus—in patients with cluster headache<sup>68</sup> (but not those with migraine)<sup>69</sup> compared with healthy volunteers. In terms of the stereotactic coordinates, the lesion occurs in about the same area in which activation during an acute cluster headache attack is noted in PET (figure 2).<sup>57</sup> This work has even led to the successful introduction of a therapeutic target using deep brain stimulation of the posterior hypothalamic grey matter.<sup>70</sup> So far, successful operations have been reported in 20 patients with intractable chronic cluster headache,<sup>70–72</sup> some with a follow-up of more than 4 years.<sup>71,72</sup>

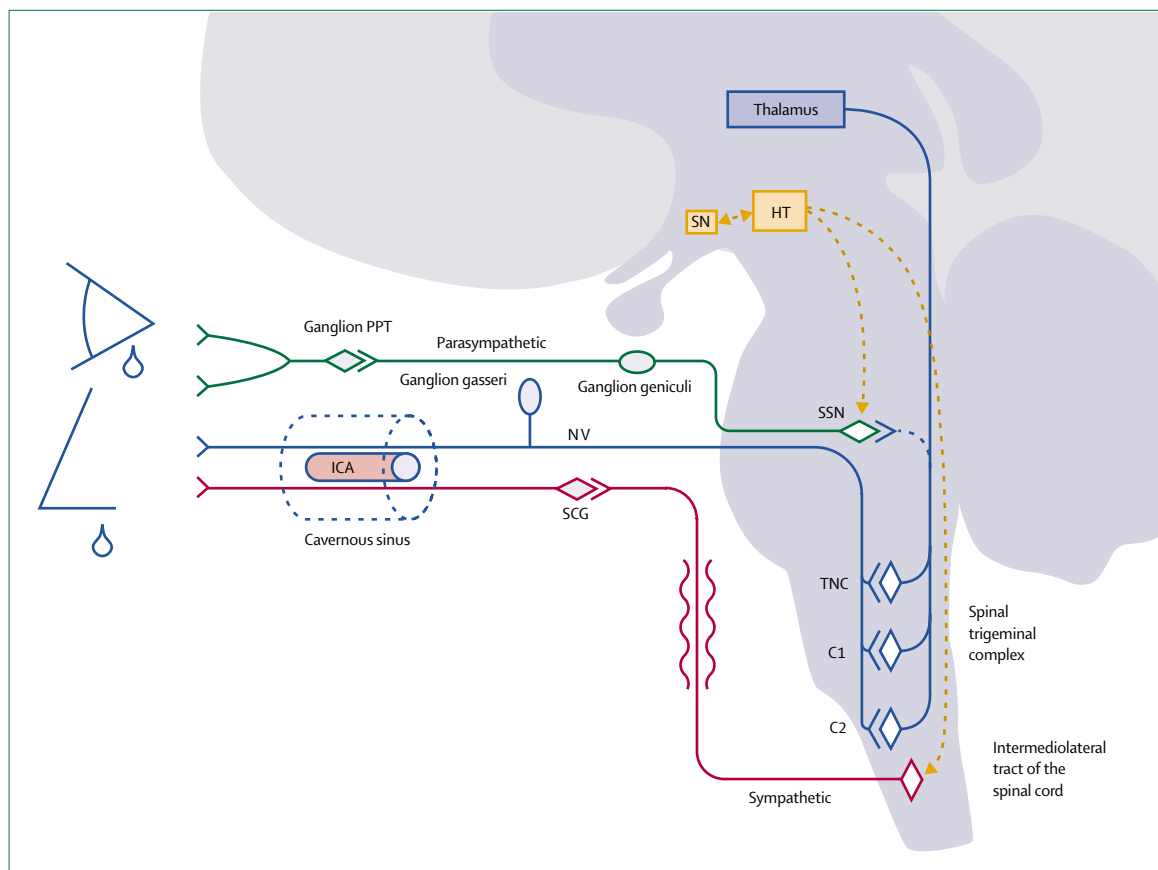
Attacks reappear when the stimulator is switched off, and disappear when it is turned on again. Notably, it

takes several days or even weeks between turning the unipolar stimulator on or off and change of the clinical picture.<sup>73</sup> The method is reversible and the procedure is well tolerated in most patients, with no substantial side-effects. However, one patient had an intracerebral hemorrhage during the operation.<sup>72</sup> This event led to the development of strict criteria and technical prerequisites for the selection of patients who should have operations.<sup>74</sup> From a clinical point of view, it is interesting that trigeminal hypaesthesia and anaesthesia did not occur in any of the patients who received hypothalamic deep brain stimulation, and that hypothalamic stimulation does not affect anaesthesia dolorosa.<sup>71</sup> This observation strengthens the hypothesis that the pain of cluster headache does not arise from a primary dysfunction of the trigeminal nerve itself, but is generated directly from the brain.<sup>23</sup> In this context, it is noteworthy that electrical stimulation of the superior sagittal sinus, a trigeminally innervated structure, activates the supraoptic nucleus and posterior hypothalamic area,<sup>75</sup> and a monosynaptic pathway connecting the hypothalamus and trigeminal nucleus has been documented.<sup>76</sup> The posterior hypothalamus is able to both decrease or enhance nociceptive responses in the trigeminal nucleus caudalis.<sup>77</sup> Little is known about the circuits and mechanisms underlying the effect of deep brain stimulation; however, activation of thalamo-cortical pathways and changes in cortical activity are probably involved.<sup>78</sup> Further research in this field is urgently needed and the recently developed possibility of combining deep brain stimulation with PET will certainly help to unravel the brain circuitry implicated in stimulation-produced analgesia.

In summary, the pathogenesis of cluster headache is complex and remains incompletely understood. It is probably better to regard the condition as a hypothalamic syndrome rather than as a simple headache. In doing so, the contributions of both peripheral and central structures are considered, and this description takes into account the hypothalamic symptoms such as aggressiveness, sleep disturbance, restlessness, and endocrine and vegetative symptoms typically encountered in many patients. Whether it is primary to the disease or only an epiphenomenon, the peripheral nervous system's role in episodic cluster headache is beyond dispute. Interestingly, the peripheral part of the trigeminal nerve is not necessarily needed for some chronic forms of the disease,<sup>19</sup> which means that the syndrome may be progressive. Whether inflammation of the walls of the cavernous sinus occurs, a process that has been thought to obliterate venous outflow and thus injure the traversing sympathetic fibres of the intracranial internal carotid artery and its branches, is controversial.<sup>35,79,80</sup> That the hypothalamus is involved, at least in primary cluster headache, seems indisputable. At a minimum, primary cluster headache is characterised by hypothalamic activation with



**Figure 2: Functional imaging studies showing specific involvement of the hypothalamus in cluster headache** (A) PET-activation studies in nine patients with cluster headache during the nitroglycerin triggered acute headache phase compared with the resting state<sup>57</sup> and (B) single-subject study in another patient during the spontaneous acute headache phase.<sup>38</sup> Activation of the inferior posterior hypothalamus (coloured area) was found ipsilateral to the headache side and is specific for this type of idiopathic headache syndrome. Even in a patient with trigemino-autonomic headache attacks (C), in whom frequency, duration, and therapeutic response allowed no clear-cut classification to one of the subtypes of trigeminal autonomic cephalgia, the same prominent activation in the hypothalamic grey matter was noted.<sup>63</sup> (D) Voxel based morphometry in 25 cluster headache patients compared with 29 healthy volunteers.<sup>68</sup> An important structural difference in grey matter was solely found in the inferior posterior hypothalamus. In terms of the stereotactic coordinates, it is virtually the same area as in the activation studies. Use of functional imaging and definition of the exact brain area that is inherent to the disease led to the successful introduction of a therapeutic target using deep brain stimulation of the posterior hypothalamic grey matter.<sup>70,71</sup>



**Figure 3: Schematic model showing most of the putative actors in pathogenesis of cluster headache**

Pain afferents from the trigeminovascular system synapse on the trigemino-cervical complex (TNC), and then project to the thalamus and lead to activation in cortical areas known to be involved in pain transmission. Either a direct effect of the hypothalamus or a reflex activation of the parasympathetic outflow from the superior salivatory nucleus (SSN) predominantly through the pterygopalatine (sphenopalatine) ganglion, leads to the parasympathetic symptoms ipsilateral to the pain. A third-order sympathetic nerve lesion, thought to be caused by vascular changes in the cavernous sinus loggia with subsequent irritation of the local plexus of nerve fibres, results in a partial Horner's syndrome. The key site in the CNS for triggering the pain and controlling the cycling aspects is in the posterior hypothalamic grey matter region, modulated by phase-shifting in the suprachiasmatic nuclei. HT=hypothalamus. ICA=internal carotid artery. NV=trigeminal nerve. PPT=pterygopalatine. SCG=superior cervical ganglion. SN=suprachiasmatic nucleus.

secondary activation of the trigemino-facial reflex, probably via a trigemino-hypothalamic pathway (figure 3).<sup>76</sup> In long-standing chronic cluster headache, the autonomic symptoms and headache may be generated entirely through central mechanisms, as activation of the trigemino-facial reflex is no longer necessary to display the full clinical picture.<sup>19</sup>

### Diagnosis

The diagnosis of cluster headaches is exclusively clinical. The International Classification of Headache Disorders<sup>3</sup> uses explicit diagnostic criteria (panel), which are "unambiguous, precise and with as little room for interpretation as possible". That at least 14 synonyms for cluster headache have been used in the past shows the an earlier lack of understanding of aetiology, and the importance of operational, explicit diagnostic criteria for research and clinical practice. Cluster headache, in its typical form, is unmistakable. However, no single

instrumental examination can define, ensure, or differentiate idiopathic headache syndromes.<sup>81</sup> Nevertheless, in the clinical setting, the use of neuroimaging (cranial CT, MRI, MR angiography, etc) in patients with headache varies widely. Electrophysiological and laboratory examinations, including examination of the CSF, are not helpful. For the initial diagnosis and in the case of an abnormal neurological examination, a cranial CT scan and cranial MRI should be considered, to exclude abnormalities of the brain. Mass lesions or malformations in the midline have been described in patients with symptomatic cluster headache, especially older patients.<sup>82,83</sup>

### Differential diagnosis

The trigemino-autonomic cephalgias are outlined in the revised version of the classification of the International Headache Society.<sup>3</sup> All these syndromes have two features in common: short-lasting, unilateral, severe

See <http://www.i-h-s.org>

**Panel: International classification of headache disorders<sup>3</sup>**

**Criteria**

- (A) At least five headache attacks fulfilling criteria B-D
  - (B) Severe or very severe unilateral orbital, supraorbital, and/or temporal headache attacks, which last untreated for 15–180 min. During part (but less than half) of the time course of the cluster headache, attacks may be less severe, less frequent, or of shorter or longer duration
  - (C) The headache is accompanied by at least one of the following symptoms ipsilateral to the pain:
    - (1) Conjunctival injection or lacrimation
    - (2) Nasal congestion and/or rhinorrhoea
    - (3) Eyelid oedema
    - (4) Forehead and facial sweating
    - (5) Miosis and/or ptosis
    - (6) A sense of restlessness and agitation
  - (D) The attacks have a frequency from one every other day to eight per day
  - (E) History and physical and neurological examination do not suggest any other disorder, or they are ruled out by appropriate investigations
- Episodic cluster headache*  
At least two cluster periods lasting 7 days to 1 year separated by pain-free periods lasting >1 month
- Chronic cluster headache*  
Attacks occur for more than 1 year without remission or with remission <1 month.
- Probable cluster headache*  
Attacks fulfilling all but one of the criteria for cluster headache

and rhythmicity of the attacks,<sup>59</sup> in the intensity of pain and autonomic symptoms, and in treatment options (table).<sup>55,84</sup> There are reports of aura in cluster headache<sup>85</sup> and even a “hemiplegic cluster”.<sup>86</sup> There seem to be some cases of cluster headache without headache,<sup>44</sup> as well as the opposite: cluster headache without autonomic symptoms,<sup>7,87</sup> and even bilateral cases.<sup>8</sup> In a series of case reports presenting three atypical cluster headaches, it has been suggested that as more cluster patients are seen by headache specialists, new forms of this well-defined primary headache syndrome will be identified.<sup>88</sup> However, the concept of trigemino-autonomic syndromes is certainly useful for clinicians seeking a pathophysiological understanding of the primary neurovascular headaches, and allows us to put the various treatment and prevention strategies in context.

**Management**

The guidelines of the International Headache Society<sup>3</sup> represent a compromise between scientific rigour and practicality. However, because the syndrome is quite rare, it is still essential to collect and publish large case series regarding clinical manifestations, differences between the sexes, and treatment options in cluster headache. Case reports are also important as it becomes clearer that chronic headache is part of a larger spectrum of primary headache syndromes<sup>59</sup> and that overlap with other trigemino-autonomic headache syndromes may occur.<sup>89,90</sup>

headache attacks accompanied by typical autonomic symptoms. The syndromes differ in duration, frequency,

The treatment of cluster headache is based on empirical data rather than on a pathophysiological

	Cluster headache	Paroxysmal hemicrania	SUNCT syndrome	Hemicrania continua	Hypnic headache
<b>Epidemiology</b>					
Sex (male:female)	3:1	1:3	8:1	1:1.8	1.8:1
Prevalence	0.9%	0.02%	very rare	rare	very rare
Age of onset (years)	28–30	20–40	20–50	20–30	40–70
<b>Pain</b>					
Quality	Piercing, throbbing	Piercing	Stabbing	Pressing	Pulsating
Intensity	Extremely high	High	Moderate to high	Moderate	moderate
Localisation	Periorbital	Orbital, temporal	Orbital, temporal	Unilateral, temporal	bifrontal, median
Duration of attack	15–120 min	2–45 min	5–250 s	Fluctuating, constant, with superimposed attacks	30–120 min
Frequency of attacks	1–8 per day	1–40 per day	1 per day to 30 per h		1–2 per day
Autonomic symptoms	++	++	+	(+)	–
Circadian rhythmicity	+	(–)	–	–	+
Alcohol trigger	++	(+)	(–)	–	–
<b>Treatment</b>					
Acute treatment of choice	100% oxygen, 15 L/min intranasal lidocaine, sumatriptan	Aspirin (naproxen, diclofenac)	None	Diclofenac	Caffeine
Preventive treatment of choice	Verapamil, lithium, corticosteroids, topiramate, methysergide	Indomethacin	Lamotrigine	Indometacin	Verapamil, lithium
Second-line treatment and occasional reports	Valproic acid, ergotamine, melatonin, pizotifen, indometacin	Corticosteroids, verapamil, acetazolamide, coxib	Gabapentin, carbamazepine, valproic acid, topiramate	Piroxicam, naproxen, caffeine, corticosteroids	Flunarizine, atenolol, indometacin

Adapted from references 55 and 84.

**Table: Comparison of cluster headache with related headache syndromes**

concept.<sup>89,91</sup> Although the headaches are usually extremely painful, drug treatment in cluster headache shows a placebo rate similar to that observed in treatment of migraine<sup>92</sup>—about 30%. In general, cluster headache treatment can be divided into acute therapy for stopping individual attacks and prophylactic therapy for preventing recurrent attacks during the cluster period.<sup>64,78,93</sup> Non-drug treatment is ineffective in nearly all patients.

### Acute treatment

Inhalation of pure oxygen via a non-rebreathing facial mask, with a flow rate of at least 7 L/min (sometimes >10 L/min), is effective at stopping cluster headache attacks.<sup>94,95</sup> The inhalation should be for 20 min in a sitting, upright position. No contra-indications are known for the use of oxygen; it is safe and has no side-effects. In some patients, oxygen is effective even when the pain is most intense, whereas in others the attack is delayed for minutes to hours, rather than completely aborted. In the latter case, oxygen intake must be restricted; otherwise, the frequency of attacks may increase. About 60% of all patients with cluster headache respond to this treatment with a substantial reduction in pain within 20–30 min.<sup>96,97</sup> A disadvantage of oxygen is that patients must have continuous access to the oxygen supply (usually an oxygen tank and regulator), which may be impractical. Although hyperbaric oxygen has been much discussed as a therapeutic option, a placebo-controlled, double-blind trial has confirmed unambiguously that it is ineffective in preventing cluster headache attacks.<sup>98</sup>

In double-blind, placebo-controlled trials, the 5-HT<sub>1B/D</sub> agonist sumatriptan injected subcutaneously was effective in about 75% of all cluster headache patients (ie, pain-free within 20 min).<sup>99–101</sup> It is safe, with no evidence of tachyphylaxis or rebound in most patients, even after frequent use.<sup>102–104</sup> Contraindications are cardiovascular and cerebrovascular disorders and untreated arterial hypertension. The most uncomfortable side-effects are chest pain and distal paresthesia.<sup>105</sup> In open and double-blind, placebo-controlled trials, sumatriptan nasal spray 20 mg<sup>106,107</sup> and oral zolmitriptan 10 mg<sup>108</sup> were also effective within 30 min. I have found 5 mg zolmitriptan nasal spray to be highly effective (unpublished data). The pre-emptive use of 5-HT<sub>1B/D</sub> agonists (triptans) in cluster headache remains controversial. 100 mg oral sumatriptan given three times a day was not effective in preventing cluster headache attacks in a placebo-controlled trial.<sup>109</sup> In open trials, 40 mg eletriptan per day<sup>110</sup> or 2.5–5.0 mg naratriptan per day<sup>111</sup> reduced the number of cluster headache attacks.

Oral ergotamine has been used in the treatment of cluster headache attacks for more than 50 years<sup>46,112</sup> and is effective when given very early in the attack. It has been recommended as an aerosol spray for the

treatment of acute cluster headache.<sup>113</sup> However, modern trials are scarce. The intranasal application of dihydroergotamine in cluster headache attacks was no better than placebo in a single trial.<sup>114</sup> Recently, the intravenous application of 1 mg dihydroergotamine over 3 days has been shown to be effective in stopping severe cluster attacks in an open retrospective trial.<sup>115</sup> Use of ergotamine for short-term prophylaxis has also been studied. Ergotamine suppositories need a long time until the onset of effectiveness; a dose of 2 mg in the evening has been proposed to prevent cluster headache attacks during the night.<sup>89,112</sup>

The nasal application of lidocaine (1 mL with a concentration of 4–10%, ipsilateral to the pain; the head should be reclined by 45° and rotated to the affected side by 30° to 40°) is effective in at least a third of patients.<sup>116–118</sup> The drug is thought to block the sphenopalatine fossa region. The use of lidocaine evolved from investigations to determine whether the observed clinical usefulness of cocaine in aborting acute cluster headache attacks<sup>119</sup> was due to the drug's anaesthetic or euphoric properties.

### Prioritisation of acute therapy

Because of the rapid onset and short time to peak intensity of cluster headache pain, subcutaneous sumatriptan is the treatment of choice. The absorption and pharmacological actions of oral medications are usually too slow. Oxygen is the other standard treatment. Topical application of lidocaine is comparatively less efficient and has inconsistent effects. However, one could argue that every patient should try it at least once, since if it works, it is easy to administer and has no systemic side-effects, which is important since patients can sometimes have as many as eight attacks a day.

### Preventive pharmacotherapy

The importance of an effective preventive regimen cannot be overstated. Since many patients have between one and eight attacks a day, repeated attempts at abortive therapy may result in overmedication or toxicity. The primary goal of preventive therapy is to suppress attacks and to maintain this suppression over the expected duration of the cluster period. To achieve this goal, an individual treatment regimen must be formulated with the patient. In episodic cluster headache, medication should be withdrawn when the expected cluster period is over. In chronic cluster headache, medication should be gradually reduced once every other month, to assess whether it is still necessary.

The cornerstone of maintenance prophylaxis is verapamil. A daily dose of 240–320 mg verapamil is the established treatment of choice in the prophylaxis of episodic and chronic cluster headache,<sup>64,91</sup> although few sufficient double-blind, placebo-controlled trials are available. Results of placebo-controlled trials showed efficacy of both verapamil and lithium, with verapamil

acting more rapidly than lithium.<sup>120,121</sup> In some cases, a daily dose of more than 720 mg verapamil may be necessary.<sup>64,122</sup> Because of this apparent dose-response relation, a total daily dose of 480–720 mg is recommended before the treatment is regarded as unsuccessful. Regular ECG monitoring is required. Side-effects of verapamil are bradycardia, oedema, gastrointestinal discomfort, constipation, and dull headache.<sup>123</sup> However, the drug is generally well tolerated and can be used safely in conjunction with sumatriptan, ergotamine, corticosteroids, and other preventive agents. No evidence is available for an optimal dosage for verapamil. An increase of 80 mg every 3 days is recommended. The full effect of verapamil can be expected within 2–3 weeks. Both the regular and extended-release preparations have been shown to be useful, but no direct comparative trials are available. Since verapamil is usually well tolerated, it is also the drug of choice for continuous treatment in chronic cluster headache. In the first 2 weeks of verapamil administration, steroids may also be given (30–100 mg prednisone or 2×4 mg dexamethasone per day). In two small open studies, nimodipine was also effective.<sup>124,125</sup>

Lithium has been studied in cluster headache prophylaxis in a daily dose of 600–1500 mg in more than 20 open trials.<sup>126</sup> The proportion of patients that had an improvement in chronic cluster headache was reported to be as high as 78% (63% in episodic cluster headache). A placebo-controlled trial, however, did not reproduce the beneficial effect in episodic cluster headache.<sup>127</sup> However, in a comparative, double-blind crossover study, lithium and verapamil showed similar efficacy (with a more rapid improvement with verapamil) and tolerability was better with verapamil.<sup>128</sup> The concentration of the drug in the plasma should be monitored and kept between 0.6 mmol/L and 1.2 mmol/L.<sup>129</sup> Regular monitoring of liver, renal, and thyroid function and of electrolytes is needed. Major side-effects are hyperthyroidism, tremor, and renal dysfunction. As lithium in general has a narrow therapeutic window, it is particularly recommended for chronic cluster headache when other drugs are ineffective or contraindicated.

Methysergide has been recommended for episodic cluster headache,<sup>16,130–133</sup> but no placebo-controlled, double-blind studies are available. In open studies, the number of patients who benefited from methysergide ranged from 20% to 73%; the drug was more effective in episodic cluster headache.<sup>134</sup> The doses given in the open studies varied from 4 mg to 16 mg. Usually, methysergide is administered at a daily dose of 4–8 mg and can be increased up to 12 mg (starting with 1 mg per day). Methysergide is metabolised to an active metabolite, methylergometrine,<sup>135</sup> and should be used with caution when patients are receiving other ergotamine derivatives or triptans. The short-term side-effects include nausea, muscle cramps, abdominal pain,

and pedal oedema. Since a high incidence of pulmonary and retroperitoneal fibrosis is seen with long-term use, the continuous use of methysergide is limited to 3–4 months.<sup>136,137</sup>

No adequate randomised, placebo-controlled trials are available for the use of corticosteroids in cluster headache. Several open studies and case series have been published and reviewed.<sup>16,130</sup> All the open studies confirmed the clinically well-known efficacy of steroids given in different regimens (>30 mg prednisone per day; 2×4 mg dexamethasone per day). These drugs are a very effective option for initial prophylaxis, rapidly suppressing attacks during the time needed for the longer-acting preventive agents to take effect. However, some patients are attack-free only with steroids, and continuous administration of steroids is necessary. As with verapamil, no evidence for the best regimen of steroid administration is available. For the beginning of steroid treatment, 60–100 mg of prednisone given once a day for at least 5 days is recommended, then decreasing the dose by 10 mg every day. About 70–80% of all cluster headache patients respond to steroids. Intravenous and oral application of steroids can also be successfully combined.<sup>138</sup>

#### *Refractory patients*

In 10–20% of patients, the above medications are not effective or the cluster periods develop resistance. Intolerance or contra-indications may further limit standard treatments. The following medications have some importance as third-line therapy, mostly based on small, open studies.

The antiserotonergic drug pizotifen (3 mg per day) has been shown to be effective in cluster headache prophylaxis in a single-blind, placebo-controlled trial.<sup>139</sup> However, a review of seven small studies,<sup>140</sup> suggests that pizotifen has only a modest effect. Side-effects such as tiredness and weight gain further limit this drug's use. Valproic acid has been studied in three open trials, with inconsistent results.<sup>141–143</sup> These trials suggest that valproic acid can be tried as a drug of third choice in a daily dose of 5–20 mg per kg bodyweight. Likewise, some open studies suggest that topiramate is effective in the prophylaxis of cluster headache.<sup>144–147</sup> The recommended dose is at least 100 mg per day, with a starting dose of 25 mg. The main side-effects are cognitive disturbances, paraesthesias, and weight loss. The drug is contra-indicated in patients with nephrolithiasis.

For the ipsilateral intranasal application of capsaicin, two open trials<sup>148,149</sup> and one double-blind, placebo-controlled trial<sup>150</sup> have been published, showing efficacy in about two-thirds of patients after repeated application. Intranasal application of civamide showed a modest efficacy in a double-blind, placebo-controlled study.<sup>151</sup>

10 mg of oral melatonin was effective in a double-blind, placebo-controlled study.<sup>152</sup> In otherwise refractory



cluster headache, however, melatonin did not produce any additional efficacy.<sup>153</sup> There is meagre evidence from a small open study for the efficacy of baclofen (15–30 mg),<sup>154</sup> and there is no sufficient evidence for the efficacy of botulinum toxin<sup>155</sup> or transdermal clonidine<sup>156</sup> in the prophylactic treatment of cluster headache.

Although there is no valid evidence that combinations of various prophylactic drugs work better in cluster headache, some patients may do better with a combination than with extensive high doses of a single drug. In clinical practice, a combination of drugs is often needed, generally using a moderate dose of verapamil (240–480 mg) as the standard medication and any of the above prophylactic drugs as add-on therapy. On the basis of a consensus obtained at the 9th International Headache research seminar, some combinations of drugs have been recommended in patients otherwise refractory to single preventive treatment.<sup>157</sup>

#### *Surgical treatment*

If all drugs are ineffective and a secondary cluster headache has been excluded, surgical treatment can be discussed with the patient. Surgical procedures should be considered with great caution because no reliable long-term observational data are available and because they can induce trigeminal neuralgia or anaesthesia dolorosa. Different methods have been suggested to prevent cluster headache: application of glycerol or local anaesthetics into the cisterna trigeminalis of the Gasserian ganglion;<sup>158</sup> radiofrequency rhizotomy of the Gasserian ganglion<sup>159</sup> or of the trigeminal nerve;<sup>160</sup> microvascular decompression;<sup>161</sup> and resection or blockade of the greater superficial petrosal nerve<sup>162</sup> or of the ganglion sphenopalatinum.<sup>163</sup> However, there are also case reports of the complete inefficacy of surgical treatment in cluster headache and related syndromes.<sup>19,164–166</sup> In some cases, blockade of the greater occipital nerve was effective, and this approach may be tried before any other surgical procedure.<sup>167,168</sup> In general, any surgical procedure on peripheral trigeminal structures in episodic cluster headache must be judged with great caution, as the nature of the disorder is to remit. On the other hand, in chronic cluster headache, there is strong evidence that even a complete trigeminal denervation is not effective.<sup>19</sup> Deep brain stimulation of the posterior inferior hypothalamus has been shown to be effective in most of a sample of patients with intractable cluster headache.<sup>70–73</sup> Recommendations for the selection of patients for this procedure have been published.<sup>74</sup>

#### *Prioritisation of preventive therapy*

Patients with chronic and long-lasting active periods of episodic cluster headache should be principally treated with verapamil. Because of the relatively long time required for increasing the dosages of verapamil until it takes effect, corticosteroids, ergotamine, or even triptans

with a long half-life can be used as an effective initial prophylactic option. Methysergide or corticosteroids are the medication of choice in short-lasting active cluster periods (less than 2 months). Lithium and valproic acid are thought to be helpful, but only as second-line therapy. When patients cannot tolerate standard medications, or these are contraindicated, combinations of other drugs should be explored. Corticosteroids should, if at all possible, be used only for short-term prophylaxis. Surgical procedures should be viewed with great caution; despite excellent results, even hypothalamic deep brain stimulation must be regarded as highly experimental.

#### **Unresolved issues and the future**

Why do cluster headache attacks start and, more importantly, why do they stop after a fairly defined period of time? What exactly causes the switch from inactive to active periods, and vice versa? The role of the human clock system implicates the suprachiasmatic nucleus and, consequently, photoperiod changes have been thought to be a crucial external factor. However, this theory implies that light therapy should work, whereas in my experience it does not. Moreover, melatonin has no effect, and in most patients the circadian rhythm is indeed stereotyped (highly homogeneous), whereas the annual rhythm is highly individual.

The relevance of the high proportion of smokers among patients with cluster headache is not known. In the active period, cluster headache is reliably triggered by alcohol, histamine, and nitrates,<sup>8</sup> but the mechanism whereby these factors induce an attack is not understood. One common feature of histamine, alcohol, and nitrates is their vasodilating effect. Nitroglycerin is a pro-drug for nitric oxide, which can activate the trigeminal vascular system. However, recent data indicate that neither the vessels nor the peripheral part of the trigeminal system are needed in development of a full-blown attack.

The mechanism of the effectiveness of oxygen in treating cluster headache is not understood. Reductions in cerebral blood flow, cerebral vasoconstriction, activation of descending inhibitory neurons from the brainstem, and an abnormal chemoreceptor sensitivity in cluster headache have been suggested. Notably, none of the preventive medicines used in cluster headache are given on the basis of proven theoretical background their use is based on purely empirical evidence.

Deep brain stimulation of the hypothalamus is highly specific and successful in patients with intractable cluster headache. However, it is still highly experimental. How stimulation of an area that is thought to act as a pacemaker for acute cluster attacks can prevent these attacks is not known.

The past decade has seen remarkable progress toward unravelling the mystery of primary headache disorders.

Because cluster headache and trigeminal autonomic headaches are much less common than migraine, most funding for headache research goes into migraine. Consequently, we have excellent quality-of-life data and a fairly accurate neurobiological model for migraine, with substantial knowledge of the genetic basis and thorough data on peripheral and central pain modulation. This information has led to a highly specific acute treatment designed just for migraine, notably the triptans, which, incidentally, also work in cluster headache but not, for example, in tension type headache. Understanding the fascinating basis of a relapsing-remitting headache syndrome on the basis of a precise circadian and circannual mechanism will not only benefit patients, but will also help to unravel the physiological interaction between the internal biological clock and pain perception and control. Bearing in mind that the excruciating pain in cluster headache has led to it being coined a “suicide headache”, we need to accept the challenge.

#### Conflict of interest statement

I declare that I have no conflict of interest.

#### Acknowledgments

I thank M Leone, P J Goadsby, and other colleagues for many inspiring discussions and advice. I am also grateful to A Draganski and U Bingel for helping me with figure 3, T Sprenger for providing figure 3 parts B and C, A Draganski for editing figure 4, and E Schoell for reading the manuscript. This work was supported by a grant of the Deutsche Forschungsgemeinschaft (MA 1862/2) and by a grant of the BMBF (project number 371 57 01).

#### References

- Geweke LO. Misdiagnosis of cluster headache. *Curr Pain Headache Rep* 2002; **6**: 76–82.
- D'Amico D, Rigamonti A, Solari A, et al. Health-related quality of life in patients with cluster headache during active periods. *Cephalalgia* 2002; **22**: 818–21.
- Headache Classification Committee of the International Headache Society. The International Classification of Headache Disorders, 2nd edn. *Cephalalgia* 2004; **24** (suppl 1): 1–160.
- Manzoni GC, Terzano MG, Bono G, Micieli G, Martucci N, Nappi G. Cluster headache—clinical findings in 180 patients. *Cephalalgia* 1983; **3**: 21–30.
- Drummond PD. Dysfunction of the sympathetic nervous system in cluster headache. *Cephalalgia* 1988; **8**: 181–86.
- Drummond PD. Sweating and vascular responses in the face: normal regulation and dysfunction in migraine, cluster headache and harlequin syndrome. *Clin Auton Res* 1994; **4**: 273–85.
- Ekbom K. Evaluation of clinical criteria for cluster headache with special reference to the classification of the International Headache Society. *Cephalalgia* 1990; **10**: 195–97.
- Sjaastad O, ed. Cluster headache syndrome. London: WB Saunders, 1992.
- D'Alessandro R, Gamberini G, Benassi G, Morganti G, Cortelli P, Lugaresi E. Cluster headache in the Republic of San Marino. *Cephalalgia* 1986; **6**: 159–62.
- Ekbom K, Ahlborg B, Schele R. Prevalence of migraine and cluster headache in Swedish men of 18. *Headache* 1978; **18**: 9–19.
- Kudrow L. Cluster headache, mechanism and management. 1st edn. New York: Oxford University Press, 1980.
- Russell MB. Epidemiology and genetics of cluster headache. *Lancet Neurol* 2004; **3**: 279–83.
- Bahra A, May A, Goadsby PJ. Cluster headache: a prospective clinical study with diagnostic implications. *Neurology* 2002; **58**: 354–61.
- Sjaastad O, Bakketeig LS. Cluster headache prevalence. Vaga study of headache epidemiology. *Cephalalgia* 2003; **23**: 528–33.
- Ekbom K, Svensson DA, Traff H, Waldenlind E. Age at onset and sex ratio in cluster headache: observations over three decades. *Cephalalgia* 2002; **22**: 94–100.
- Ekbom K, Hardebo JE. Cluster headache: aetiology, diagnosis and management. *Drugs* 2002; **62**: 61–69.
- May A, Goadsby PJ. The trigeminovascular system in humans: pathophysiological implications for primary headache syndromes of the neural influences of the cerebral circulation. *J Cereb Blood Flow Metab* 1999; **19**: 115–27.
- May A, Bahra A, Büchel C, Frackowiak R, Goadsby P. PET and MRA findings in cluster headache and MRA in experimental pain. *Neurology* 2000; **55**: 1328–35.
- Matharu MS, Goadsby PJ. Persistence of attacks of cluster headache after trigeminal nerve root section. *Brain* 2002; **125**: 976–84.
- Leone M, Attanasio A, Croci D, et al. Neuroendocrinology of cluster headache. *Ital J Neurol Sci* 1999; **20**: S18–S20.
- Leone M, Russell MB, Rigamonti A, et al. Increased familial risk of cluster headache. *Neurology* 2001; **56**: 1233–36.
- Goadsby PJ. Pathophysiology of cluster headache: a trigeminal autonomic cephalgia. *Lancet Neurol* 2002; **1**: 251–57.
- Manzoni GC. Cluster headache and lifestyle: remarks on a population of 374 male patients. *Cephalalgia* 1999; **19**: 88–94.
- Turkewitz LJ, Wirth O, Dawson GA, Casaly JS. Cluster headache following head injury: a case report and review of the literature. *Headache* 1992; **32**: 504–06.
- Reik L Jr. Cluster headache after head injury. *Headache* 1987; **27**: 509–10.
- Couturier EG, Hering R, Steiner TJ. The first report of cluster headache in identical twins. *Neurology* 1991; **41**: 761.
- Sorensen SA, Araki S. Genetics. In: Olesen J, Tfelt-Hansen P, Welch KMA, eds. The headaches. New York: Raven Press, 1993: 21–27.
- Sjaastad O, Shen JM, Stovner LJ, Elsas T. Cluster headache in identical twins. *Headache* 1993; **33**: 214–17.
- Russell MB, Andersson PG, Thomsen LL. Familial occurrence of cluster headache. *J Neurol Neurosurg Psychiatry* 1995; **58**: 341–43.
- El Amrani M, Ducros A, Boulan P, et al. Familial cluster headache: a series of 186 index patients. *Headache* 2002; **42**: 974–77.
- Russell MB, Andersson PG, Thomsen LL, Iseorius L. Cluster headache is an autosomal dominantly inherited disorder in some families: a complex segregation analysis. *J Med Genet* 1995; **32**: 954–56.
- Lampl C. Childhood-onset cluster headache. *Pediatr Neurol* 2002; **27**: 138–40.
- Evers S, Frese A, Majewski A, Albrecht O, Husstedt IW. Age of onset in cluster headache: the clinical spectrum (three case reports). *Cephalalgia* 2002; **22**: 160–62.
- Isler H. Episodic cluster headache from a textbook of 1745: Van Swieten's classic description. *Cephalalgia* 1993; **13**: 172–74.
- Hardebo JE. Activation of pain fibers to the internal carotid artery intracranially may cause the pain and local signs of reduced sympathetic and enhanced parasympathetic activity in cluster headache. *Headache* 1991; **31**: 314–20.
- Goadsby PJ, Edvinsson L. Human in vivo evidence for trigeminovascular activation in cluster headache. Neuropeptide changes and effects of acute attacks therapies. *Brain* 1994; **117**: 427–34.
- Fanciullacci M, Pietrini U, Gatto G, Boccuni M, Sicuteri F. Latent dysautonomic pupillary lateralization in cluster headache. A pupillometric study. *Cephalalgia* 1982; **2**: 135–44.
- Waldenlind E, Drummond PD. Synthesis of cluster headache pathophysiology. In: Olesen J, Tfelt Hansen P, Welch KM, eds. The headaches. Philadelphia: Lippincott Williams and Wilkins, 1999.
- Hardebo JE. How cluster headache is explained as an intracavernous inflammatory process lesioning sympathetic fibres. *Headache* 1994; **34**: 125–31.
- Gardner W, Stowell A, Dutlinger R. Resection of the greater superficial petrosal nerve in the treatment of unilateral headache. *J Neurosurg* 1947; **4**: 105–14.
- Frese A, Evers S, May A. Autonomic activation in experimental trigeminal pain. *Cephalalgia* 2003; **23**: 67–68.
- Drummond PD. Autonomic disturbances in cluster headache. *Brain* 1988; **111**: 1199–209.

- 43 Russell M, Andersson GB. Clinical intra- und interfamilial variability of cluster headache. *Eur J Neurol* 1995; **1**: 253–57.
- 44 Leone M, Rigamonti A, Bussone G. Cluster headache sine headache: two new cases in one family. *Cephalalgia* 2002; **22**: 12–14.
- 45 Martins I, Gouveia R, Antunes J. Double dissociation between autonomic symptoms and pain in cluster headache. *Cephalalgia* 2005; **25**: 398–400.
- 46 Kunkle EC, Pfeiffer J, Wilhoit WM, Hamrick J. Recurrent brief headache in cluster pattern. *Trans Am Neurol Assoc* 1952; **27**: 240–43.
- 47 Ekblom K. Nitroglycerin as a provocative agent in cluster headache. *Arch Neurol* 1968; **19**: 487–93.
- 48 Ekblom K. Patterns of cluster headache with a note on the relations to angina pectoris and peptide ulcer. *Acta Neurol Scand* 1970; **46**: 225–37.
- 49 Kudrow L. The cyclic relationship of natural illumination to cluster period frequency. *Cephalalgia* 1987; **7**: 76–81.
- 50 Strittmatter M, Hamann GF, Grauer M, et al. Altered activity of the sympathetic nervous system and changes in the balance of hypophyseal, pituitary and adrenal hormones in patients with cluster headache. *Neuroreport* 1996; **7**: 1229–34.
- 51 Nelson RF. Testosterone levels in cluster and non-cluster migrainous patients. *Headache* 1978; **18**: 265–67.
- 52 Leone M, Patrino G, Vescovi A, Bussone G. Neuroendocrine dysfunction in cluster headache. *Cephalalgia* 1990; **10**: 235–39.
- 53 Chazot G, Claustrat B, Brun J, Jordan D, Sassolas G, Schott B. A chronobiological study of melatonin, cortisol, growth hormone and prolactin secretion in cluster headache. *Cephalalgia* 1984; **4**: 213–20.
- 54 Ferrari E, Canepari C, Bossolo PA, et al. Changes of biological rhythms in primary headache syndromes. *Cephalalgia* 1983; **3**: 58–68.
- 55 Waldenlind E, Gustafsson SA, Ekblom K, Wetterberg L. Circadian secretion of cortisol and melatonin in cluster headache during active cluster periods and remission. *J Neurol Neurosurg Psychiatry* 1987; **50**: 207–13.
- 56 Hofman MA, Zhou JN, Swaab DF. Suprachiasmatic nucleus of the human brain: an immunocytochemical and morphometric analysis. *J Comp Neurol* 1996; **305**: 552–56.
- 57 May A, Bahra A, Büchel C, Frackowiak RSJ, Goadsby PJ. Hypothalamic activation in cluster headache attacks. *Lancet* 1998; **352**: 275–78.
- 58 Sprenger T, Boecker H, Tolle TR, Bussone G, May A, Leone M. Specific hypothalamic activation during a spontaneous cluster headache attack. *Neurology* 2004; **62**: 516–17.
- 59 Goadsby PJ, Lipton RB. A review of paroxysmal hemicranias, SUNCT syndrome and other short-lasting headaches with autonomic feature, including new cases. *Brain* 1997; **120**: 193–209.
- 60 May A, Bahra A, Büchel C, Turner R, Goadsby PJ. Functional magnetic resonance imaging in spontaneous attacks of SUNCT: short-lasting neuralgiform headache with conjunctival injection and tearing. *Ann Neurol* 1999; **46**: 791–94.
- 61 Sprenger T, Valet M, Platzler S, Pfaffenrath V, Steude U, Tolle TR. SUNCT: bilateral hypothalamic activation during headache attacks and resolving of symptoms after trigeminal decompression. *Pain* 2005; **113**: 422–26.
- 62 Cohen AS, Matharu MS, Kalisch R, Friston K, Goadsby PJ. Functional MRI in SUNCT shows differential hypothalamic activation with increasing pain. *Cephalalgia* 2004; **24**: 1098–99.
- 63 Sprenger T, Valet M, Hammes M, et al. Hypothalamic activation in trigeminal autonomic cephalgia: functional imaging of an atypical case. *Cephalalgia* 2004; **24**: 753–57.
- 64 Matharu MS, Boes CJ, Goadsby PJ. Management of trigeminal autonomic cephalgias and hemicrania continua. *Drugs* 2003; **63**: 1637–77.
- 65 Matharu MS, Cohen AS, McGonigle DJ, Ward N, Frackowiak RS, Goadsby PJ. Posterior hypothalamic and brainstem activation in hemicrania continua. *Headache* 2004; **44**: 747–61.
- 66 Weiller C, May A, Limmroth V, et al. Brain stem activation in spontaneous human migraine attacks. *Nat Med* 1995; **1**: 658–60.
- 67 Afridi SK, Matharu MS, Lee L, et al. A PET study exploring the laterality of brainstem activation in migraine using glyceryl trinitrate. *Brain* 2005; **128**: 932–39.
- 68 May A, Ashburner J, Büchel C, et al. Correlation between structural and functional changes in brain in an idiopathic headache syndrome. *Nat Med* 1999; **5**: 836–38.
- 69 Matharu MS, Good CD, May A, Bahra A, Goadsby PJ. No change in the structure of the brain in migraine: a voxel-based morphometric study. *Eur J Neurol* 2003; **10**: 53–57.
- 70 Leone M, Franzini A, Bussone G. Stereotactic stimulation of posterior hypothalamic gray matter in a patient with intractable cluster headache. *N Engl J Med* 2001; **345**: 1428–29.
- 71 Leone M, Franzini A, Broggi G, May A, Bussone G. Long-term follow-up of bilateral hypothalamic stimulation for intractable cluster headache. *Brain* 2004; **127**: 2259–64.
- 72 Schoenen J, Di Clemente L, Vandenhede M, et al. Hypothalamic stimulation in chronic cluster headache: a pilot study of efficacy and mode of action. *Brain* 2005; **128**: 940–47.
- 73 Franzini A, Ferrolli P, Leone M, Broggi G. Stimulation of the posterior hypothalamus for treatment of chronic intractable cluster headaches: first reported series. *Neurosurgery* 2003; **52**: 1095–101.
- 74 Leone M, May A, Franzini A, et al. Deep brain stimulation for intractable chronic cluster headache: proposals for patient selection. *Cephalalgia* 2004; **24**: 934–37.
- 75 Benjamin L, Levy MJ, Lasalandra MP, et al. Hypothalamic activation after stimulation of the superior sagittal sinus in the cat: a Fos study. *Neurobiol Dis* 2004; **16**: 500–05.
- 76 Malick A, Strassman RM, Burstein R. Trigeminohypothalamic and reticulohypothalamic tract neurons in the upper cervical spinal cord and caudal medulla of the rat. *J Neurophysiol* 2000; **84**: 2078–112.
- 77 Bartsch T, Levy MJ, Knight YE, Goadsby PJ. Differential modulation of nociceptive dural input to [hypocretin] orexin A and B receptor activation in the posterior hypothalamic area. *Pain* 2004; **109**: 367–78.
- 78 May A, Leone M. Update on cluster headache. *Curr Opin Neurol* 2003; **16**: 333–40.
- 79 Bovim G, Jenssen G, Ericson K. Orbital phlebography: a comparison between cluster headache and other headaches. *Headache* 1992; **32**: 408–12.
- 80 May A, Büchel C, Bahra A, Goadsby PJ, Frackowiak RSJ. Intracranial vessels in trigeminal transmitted pain: a PET study. *Neuroimage* 1999; **9**: 453–60.
- 81 Sandrini G, Friberg L, Janig W, et al. Neurophysiological tests and neuroimaging procedures in non-acute headache: guidelines and recommendations. *Eur J Neurol* 2004; **11**: 217–24.
- 82 Hannerz J. A case of parasellar meningioma mimicking cluster headache. *Cephalalgia* 1989; **9**: 265–69.
- 83 Purdy RA, Kirby S. Headaches and brain tumors. *Neurol Clin* 2004; **22**: 39–53.
- 84 May A, Evers S, Straube A, Pfaffenrath V, Diener H. Therapie und Prophylaxe von Cluster Kopfschmerzen und anderen Trigemino-Autonomem Kopfschmerzen. Überarbeitete Empfehlungen der Deutschen Migräne- und Kopfschmerzgesellschaft. *Nervenheilkunde* 2004; **23**: 478–90.
- 85 Silberstein SD, Niknam R, Rozen TD, Young WB. Cluster headache with aura. *Neurology* 2000; **54**: 219–21.
- 86 Siow HC, Young WB, Peres MF, Rozen TD, Silberstein SD. Hemiplegic cluster. *Headache* 2002; **42**: 136–39.
- 87 Vigil M, Zebenholzer K, Wessely P. Cluster headache without autonomic symptoms? *Cephalalgia* 2001; **21**: 926–27.
- 88 Rozen TD. Atypical presentations of cluster headache. *Cephalalgia* 2002; **22**: 725–29.
- 89 Dodick D, Rozen T, Goadsby P, Silberstein S. Cluster headache. *Cephalalgia* 2000; **20**: 787–803.
- 90 Goadsby PJ. Short-lasting primary headaches: focus on trigeminal automatic cephalgias and indomethacin-sensitive headaches. *Curr Opin Neurol* 1999; **12**: 273–77.
- 91 May A. Headaches with (ipsilateral) autonomic symptoms. *J Neurol* 2003; **250**: 1273–78.
- 92 Nilsson Remahl AI, Laudon Meyer E, Cordonnier C, Goadsby PJ. Placebo response in cluster headache trials: a review. *Cephalalgia* 2003; **23**: 504–10.
- 93 Leone M. Chronic cluster headache: new and emerging treatment options. *Curr Pain Headache Rep* 2004; **8**: 347–52.
- 94 Kudrow L. Response of cluster headache attacks to oxygen inhalation. *Headache* 1981; **21**: 1–4.

- 95 Fogan L. Treatment of cluster headache. A double-blind comparison of oxygen v air inhalation. *Arch Neurol* 1985; **42**: 362–63.
- 96 Ekblom K. Treatment of cluster headache: clinical trials, design and results. *Cephalalgia* 1995; **15**: 33–36.
- 97 Gallagher RM, Mueller L, Ciervo CA. Analgesic use in cluster headache. *Headache* 1996; **36**: 105–07.
- 98 Nilsson Remahl AI, Ansjon R, Lind F, Waldenlind E. Hyperbaric oxygen treatment of active cluster headache: a double-blind placebo-controlled cross-over study. *Cephalalgia* 2002; **22**: 730–39.
- 99 The Sumatriptan Cluster Headache Study Group. Treatment of acute cluster headache with sumatriptan. *N Engl J Med* 1991; **325**: 322–26.
- 100 Ekblom K, Monstad I, Prusinski A, Cole JA, Pilgrim AJ, Noronha D. Subcutaneous sumatriptan in the acute treatment of cluster headache: a dose comparison study. *Acta Neurol Scand* 1993; **88**: 63–69.
- 101 Stovner LJ, Sjaastad O. Treatment of cluster headache and its variants. *Curr Opin Neurol* 1995; **8**: 243–47.
- 102 Wilkinson M, Pfaffenrath V, Schoenen J, Diener HC, Steiner TJ. Migraine and cluster headache—their management with sumatriptan: a critical review of the current clinical experience. *Cephalalgia* 1995; **15**: 337–57.
- 103 Ekblom K, Krabbe A, Miceli G, et al. Cluster headache attacks treated for up to three months with subcutaneous sumatriptan (6 mg). *Cephalalgia* 1995; **15**: 230–36.
- 104 Göbel H, Lindner V, Heinze A, Ribbat M, Deuschl G. Acute therapy for cluster headache with sumatriptan: findings of a one-year long-term study. *Neurology* 1998; **51**: 908–11.
- 105 Dodick DW, Martin VT, Smith T, Silberstein S. Cardiovascular tolerability and safety of triptans: a review of clinical data. *Headache* 2004; **44** (suppl 1): S20–30.
- 106 Schuh-Hofer S, Reuter U, Kinze S, Einhaupl KM, Arnold G. Treatment of acute cluster headache with 20 mg sumatriptan nasal spray—an open pilot study. *J Neurol* 2002; **249**: 94–99.
- 107 Van Vliet JA, Bahra A, Martin V, et al. Intranasal sumatriptan in cluster headache: Randomized placebo-controlled double-blind study. *Neurology* 2003; **60**: 630–33.
- 108 Bahra A, Gawel MJ, Hardebo JE, Millson D, Breen SA, Goadsby PJ. Oral zolmitriptan is effective in the acute treatment of cluster headache. *Neurology* 2000; **54**: 1832–39.
- 109 Monstad I, Krabbe A, Miceli G, et al. Preemptive oral treatment with sumatriptan during a cluster period. *Headache* 1995; **35**: 607–13.
- 110 Zebenholzer K, Wober C, Vigl M, Wessely P. Eletriptan for the short-term prophylaxis of cluster headache. *Headache* 2004; **44**: 361–64.
- 111 Mulder LJ, Spierings EL. Naratriptan in the preventive treatment of cluster headache. *Cephalalgia* 2002; **22**: 815–17.
- 112 Ekblom K. Ergotamine tartrate orally in Horton's histaminic cephalalgia (also called Harris's ciliary neuralgia). *Acta Psychiatr Scand* 1947; **46**: 106.
- 113 Ekblom K, Krabbe AE, Paalzow G, Paalzow L, Tfelt-Hansen P, Waldenlind E. Optimal routes of administration of ergotamine tartrate in cluster headache patients. A pharmacokinetic study. *Cephalalgia* 1983; **3**: 15–20.
- 114 Andersson PG, Jespersen LT. Dihydroergotamine nasal spray in the treatment of attacks of cluster headache. A double-blind trial versus placebo. *Cephalalgia* 1986; **6**: 51–54.
- 115 Magnoux E, Zlotnik G. Outpatient intravenous dihydroergotamine for refractory cluster headache. *Headache* 2004; **44**: 249–55.
- 116 Robbins L. Intranasal lidocaine for cluster headache [see comments]. *Headache* 1995; **35**: 83–84.
- 117 Mills TM, Scoggin JA. Intranasal lidocaine for migraine and cluster headaches. *Ann Pharmacother* 1997; **31**: 914–15.
- 118 Markley HG. Topical agents in the treatment of cluster headache. *Curr Pain Headache Rep* 2003; **7**: 139–43.
- 119 Costa A, Pucci E, Antonaci F, et al. The effect of intranasal cocaine and lidocaine on nitroglycerin-induced attacks in cluster headache. *Cephalalgia* 2000; **20**: 85–91.
- 120 Bussone G. Prophylaxis of cluster headache: current views on drug choice. *Ital J Neurol Sci* 1999; **20** (2 suppl): S72–74.
- 121 Leone M, D'Amico D, Frediani F, et al. Verapamil in the prophylaxis of episodic cluster headache: a double-blind study versus placebo. *Neurology* 2000; **54**: 1382–85.
- 122 Gabai JJ, Spierings EL. Prophylactic treatment of cluster headache with verapamil. *Headache* 1989; **29**: 167–68.
- 123 Noll G, Luscher TF. Comparative pharmacological properties among calcium channel blockers: T-channel versus L-channel blockade. *Cardiology* 1998; **89** (suppl 1): 10–15.
- 124 Meyer JS, Nance M, Walker M, Zetuskys WJ, Dowell RE Jr. Migraine and cluster headache treatment with calcium antagonists supports a vascular pathogenesis. *Headache* 1985; **25**: 358–67.
- 125 de Carolis P, Baldrati A, Agati R, de Capoa D, D'Alessandro R, Sacquegna T. Nimodipine in episodic cluster headache: results and methodological considerations. *Headache* 1987; **27**: 397–99.
- 126 Ekblom K. Lithium for cluster headache: review of the literature and preliminary results of long-term treatment. *Headache* 1981; **21**: 132–39.
- 127 Steiner TJ, Hering R, Couturier EGM, Davies PTG, Whitmarsh TE. Double-blind placebo-controlled trial of lithium in episodic cluster headache. *Cephalalgia* 1997; **17**: 673–75.
- 128 Bussone G, Leone M, Peccarisi C, et al. Double blind comparison of lithium and verapamil in cluster headache prophylaxis. *Headache* 1990; **30**: 411–17.
- 129 Manzoni GC, Bono G, Lanfranchi M, Miceli G, Terzano MG, Nappi G. Lithium carbonate in cluster headache: assessment of its short- and long-term therapeutic efficacy. *Cephalalgia* 1983; **3**: 109–14.
- 130 Dodick DW, Capobianco DJ. Treatment and management of cluster headache. *Curr Pain Headache Rep* 2001; **5**: 83–91.
- 131 Campbell JK. Diagnosis and treatment of cluster headache. *J Pain Symptom Manage* 1993; **8**: 155–64.
- 132 Brandt T, Paulus W, Pöhlmann W. Cluster headache and chronic paroxysmal hemicrania: current therapy. *Nervenarzt* 1991; **62**: 329–39.
- 133 Liano H, Lopez-Zuazo I. [Prophylactic treatment of episodic forms of cluster headache]. *Rev Neurol* 1995; **23** (suppl 4): S525–29.
- 134 Olesen J, Tfelt-Hansen P, Welch K. The Headaches. 2nd edn. Philadelphia: Lippincott Williams and Wilkins, 1999: 731–40.
- 135 Bredberg U, Eijolfsson GS, Paalzow L, Tfelt-Hansen P, Tfelt-Hansen V. Pharmacokinetics of methysergide and its metabolite methylergometrine in man. *Eur J Clin Pharmacol* 1986; **30**: 75–77.
- 136 Graham J, Suby H, LeCompte P, Sadowsky N. Fibrotic disorders associated with methysergide therapy for headache. *N Engl J Med* 1966; **270**: 67–72.
- 137 Muller R, Weller P, Chemaissani A. [Pleural fibrosis as a side effect of years-long methysergide therapy]. *Dtsch Med Wochenschr* 1991; **116**: 1433–36.
- 138 Mir P, Alberca R, Navarro A, et al. Prophylactic treatment of episodic cluster headache with intravenous bolus of methylprednisolone. *Neurol Sci* 2003; **24**: 318–21.
- 139 Ekblom K. Prophylactic treatment of cluster headache with a new serotonin antagonist, BC 105. *Acta Neurol Scand* 1969; **45**: 601–10.
- 140 Speight TM, Avery GS. Pizotifen (BC-105): a review of its pharmacological properties and its therapeutic efficacy in vascular headaches. *Drugs* 1972; **3**: 159–203.
- 141 Gallagher RM, Mueller LL, Freitag FG. Divalproex sodium in the treatment of migraine and cluster headaches. *J Am Osteopath Assoc* 2002; **102**: 92–94.
- 142 Hering R, Kuritzky A. Sodium valproate in the treatment of cluster headache: an open clinical trial. *Cephalalgia* 1989; **9**: 195–98.
- 143 El Amrani M, Massiou H, Bousser MG. A negative trial of sodium valproate in cluster headache: methodological issues. *Cephalalgia* 2002; **22**: 205–08.
- 144 McGeeney BE. Topiramate in the treatment of cluster headache. *Curr Pain Headache Rep* 2003; **7**: 135–38.
- 145 Forderreuther S, Mayer M, Straube A. Treatment of cluster headache with topiramate: effects and side-effects in five patients. *Cephalalgia* 2002; **22**: 186–89.
- 146 Rozen TD. Antiepileptic drugs in the management of cluster headache and trigeminal neuralgia. *Headache* 2001; **41** (suppl 1): 25–33.
- 147 Leone M, Dodick D, Rigamonti A, et al. Topiramate in cluster headache prophylaxis: an open trial. *Cephalalgia* 2003; **23**: 1001–02.
- 148 Sicuteri F, Fusco BM, Marabini S, et al. Beneficial effect of capsaicin application to the nasal mucosa in cluster headache. *Clin J Pain* 1989; **5**: 49–53.

- 149 Fusco BM, Marabini S, Maggi CA, Fiore G, Geppetti P. Preventative effect of repeated nasal applications of capsaicin in cluster headache. *Pain* 1994; **59**: 321–25.
- 150 Marks DR, Rapoport A, Padla D, et al. A double-blind placebo-controlled trial of intranasal capsaicin for cluster headache. *Cephalalgia* 1993; **13**: 114–16.
- 151 Saper JR, Klapper J, Mathew NT, Rapoport A, Phillips SB, Bernstein JE. Intranasal civamide for the treatment of episodic cluster headaches. *Arch Neurol* 2002; **59**: 990–94.
- 152 Leone M, D'Amico D, Moschiano F, Fraschini F, Bussone G. Melatonin versus placebo in the prophylaxis of cluster headache: a double-blind pilot study with parallel groups. *Cephalalgia* 1996; **16**: 494–96.
- 153 Pringsheim T, Magnoux E, Dobson CF, Hamel E, Aube M. Melatonin as adjunctive therapy in the prophylaxis of cluster headache: a pilot study. *Headache* 2002; **42**: 787–92.
- 154 Hering-Hanit R, Gadoth N. The use of baclofen in cluster headache. *Curr Pain Headache Rep* 2001; **5**: 79–82.
- 155 Evers S, Rahmann A, Vollmer-Haase J, Husstedt IW. Treatment of headache with botulinum toxin A—a review according to evidence-based medicine criteria. *Cephalalgia* 2002; **22**: 699–710.
- 156 Leone M, Attanasio A, Grazzi L, et al. Transdermal clonidine in the prophylaxis of episodic cluster headache: an open study. *Headache* 1997; **37**: 559–60.
- 157 Tfelt-Hansen P. Prophylactic pharmacotherapy of cluster headache. In: Olesen J, Goadsby P, eds. *Cluster Headache and related conditions*. Oxford, New York: Oxford University Press, 1999: 257–63.
- 158 Ekblom K, Lindgren L, Nilsson BY, Hardebo JE, Waldenlind E. Retro-Gasserian glycerol injection in the treatment of chronic cluster headache. *Cephalalgia* 1987; **7**: 21–27.
- 159 Taha JM, Tew JM Jr. Long-term results of radiofrequency rhizotomy in the treatment of cluster headache. *Headache* 1995; **35**: 193–96.
- 160 Ford RG, Ford KT, Swaid S, Young P, Jennelle R. Gamma knife treatment of refractory cluster headache. *Headache* 1998; **38**: 3–9.
- 161 Lovely TJ, Kotsiakos X, Jannetta PJ. The surgical management of chronic cluster headache. *Headache* 1998; **38**: 590–94.
- 162 Onofrio BM, Campbell JK. Surgical treatment of chronic cluster headache. *Mayo Clin Proc* 1986; **61**: 537–44.
- 163 Sanders M, Zuurmond WW. Efficacy of sphenopalatine ganglion blockade in 66 patients suffering from cluster headache: a 12- to 70-month follow-up evaluation. *J Neurosurg* 1997; **87**: 876–80.
- 164 Black D, Dodick DW. Two cases of medically and surgically intractable SUNCT: a reason for caution and an argument for a central mechanism. *Cephalalgia* 2002; **3**: 201–04.
- 165 Jarrar RG, Black DF, Dodick DW, Davis DH. Outcome of trigeminal nerve section in the treatment of chronic cluster headache. *Neurology* 2003; **60**: 1360–62.
- 166 Donnet A, Valade D, Regis J. Gamma knife treatment for refractory cluster headache: prospective open trial. *J Neurol Neurosurg Psychiatry* 2005; **76**: 218–21.
- 167 Anthony M. Arrest of attacks of cluster headache by local steroid injection of the occipital nerve. In: Rose C, ed. *Migraine*. Basel: Karger, 1985: 169–73.
- 168 Peres MF, Stiles MA, Siow HC, Rozen TD, Young WB, Silberstein SD. Greater occipital nerve blockade for cluster headache. *Cephalalgia* 2002; **22**: 520–22.